

Simplifying neurologic assessment

By Wendi Rank, CNRN, CRNP
Board Member • American Association of Neuroscience Nurses • Philadelphia, Pa.

Neurologic assessment doesn't just take place in neuro units and the ED. A patient who doesn't have a neurologic diagnosis may also require a neuro assessment; for example, a patient with pneumonia can develop neurologic changes due to hypoxia or a post-op patient may have a neurologic deficit due to blood loss. No matter what setting you work in, you'll have to perform a neurologic assessment at some point. The value of a solid neurologic assessment can't be overstated—a small change in the assessment is indicative of a neurologic injury, and early intervention can prevent permanent damage.

Performing a neurologic assessment sends many of us into a panic. Fortunately, it doesn't have to be that way. In this article, I'll review not only how to perform a solid neurologic assessment, but also how you can tailor your assessment to the situation. I'll also give you some helpful tips to make your assessment as smooth as possible.

The comprehensive assessment

A thorough neurologic assessment will include assessing mental status, cranial nerves, motor and sensory function, pupillary response, reflexes, the cerebellum, and vital signs. However, unless you work in a neuro unit, you won't typically need to perform a sensory and cerebellar assessment. Also, most vital sign changes are a sign of end-stage neurologic injury. Therefore, we'll look at assessment of mental status, cranial nerves, motor function, and pupillary response. Although this isn't a comprehensive neurologic exam, it will yield valuable clinical information. Let's get started with mental status.

Assessing mental status

Evaluating a patient's mental status includes level of consciousness (LOC), orientation, and memory.

To assess **LOC**, you'll use the Glasgow Coma Scale (see *Glasgow Coma Scale*). LOC is crucial to test because it's the first assessment to change when there's neurologic injury. You should always elicit your patient's best level of response for an accurate assessment of LOC. Begin with speaking your patient's name in a normal tone. If he doesn't respond, say his name again in a louder tone. (If your patient is hearing-impaired, you'll need to document this; it shouldn't change his score.) If there's still no response, gently shake your patient. If you still can't get a reaction, you'll need to use painful

Glasgow Coma Scale

A decreased score in one or more of the following categories may signal an impending neurologic crisis. Add the scores for the best response in each category to achieve the total score. A total score of less than 9 indicates severe brain injury.

Test	Score	Patient's response
EYE OPENING		
Spontaneously	4	Opens eyes spontaneously
To speech	3	Opens eyes to verbal command
To pain	2	Opens eyes to painful stimulus
None	1	Doesn't open eyes in response to stimulus
MOTOR RESPONSE		
Obeys	6	Reacts to verbal command
Localizes	5	Identifies localized pain
Withdraws	4	Flexes and withdraws from painful stimulus
Abnormal flexion	3	Assumes a decorticate position
Abnormal extension	2	Assumes a decerebrate position
None	1	No response; lies flaccid
VERBAL RESPONSE		
Oriented	5	Is oriented and converses
Confused	4	Is disoriented and confused
Inappropriate words	3	Replies randomly with incorrect words
Incomprehensible	2	Moans or screams
None	1	No response

stimulation. To do this, you can use one the following techniques:

- **trapezius squeeze.** Grasp and twist the muscle that runs from the back of the neck to the shoulder.
- **sternal rub.** Make a fist, then push the broad side of your fist into the sternum and press hard enough to leave a mark on your patient's skin.
- **supraorbital pressure.** Along the bone beneath the eyebrow you'll find an indentation near the nose. Press it with your thumbs.

If these techniques elicit a reaction, it comes from the brain. But there's one more technique you'll need in your repertoire. The patient who requires painful stimuli isn't following commands; therefore, if he reacts to the painful stimuli with only one side of his body, you'll need to assess the nonreactive side. This can be done by pressing a pencil into the cuticle of one of your patient's fingers. The response you'll see will be purposeful, occurring when your patient pulls away from the pain; nonpurposeful, occurring when he moves in response to the pain but not in any meaningful way (including flexion posturing [arms bent up toward the trunk with legs extended] and extension posturing [arms extend down and legs extended], formerly called decorticate and decerebrate posturing); or no response at all. All painful stimuli should be applied for 15 to 30 seconds.

To determine **orientation**, ask detailed questions about your patient's name, where he is, and the date. Obtain as much information as you can from the question; for example, when asking the date, also ask for the month and year. Keep in mind that hospitalized patients often know the month but not the date or day of the week. Evaluate your patient's knowledge of date and time carefully; patients who are confused may still answer correctly enough that a disorder goes unnoticed. I once had a patient who was clearly confused in conversation but confidently stated the name of the hospital each time I asked where we were. Halfway through my shift, I realized he was reading the hospital's name off his roommate's sheets, which were emblazoned with our logo. For the same reason, alternate your questions with each assessment. It's impor-

tant to note that when you're assessing orientation, you're also evaluating your patient's speech.

Memory is divided into three abilities: immediate memory, short-term memory, and remote memory. To assess immediate memory, give your patient three unrelated words to remember, such as pencil, grape, and car. Have him repeat the words and ask him to remember them. After 5 minutes, ask him to repeat the words back to you.

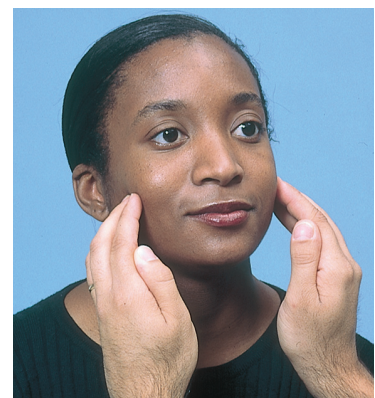
To assess short-term memory, ask your patient to describe something that happened in the last few days. The classic example is to ask him what he had for breakfast, but you'll want to be able to verify his response. You may choose to ask about a recent significant news event or a recent holiday.

Remote memory also commonly requires verification from another party. Wedding dates or children's birth dates are tests of remote memory but if you can't get confirmation, you can again try to use a news event.

Assessing the cranial nerves

The next component of the neurologic assessment is cranial nerve testing. Test the cranial nerves as follows:

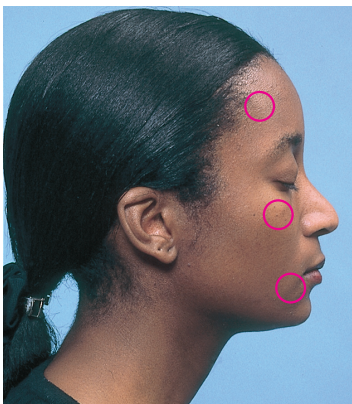
- **CN I (olfactory).** Ask your patient to identify at least two common substances such as coffee and cinnamon. Make sure his nostrils are patent before performing this test. (Note: CN I testing is usually deferred.)
- **CN II (optic).** Test visual acuity with a Snellen chart and the Rosenbaum near-vision card.



- **CN III (oculomotor), CN IV (trochlear), and CN VI (abducens).** Assess these nerves

together using the corneal light reflex test, the six cardinal positions of gaze, and the cover-uncover test. Also, inspect the size, shape, and symmetry of your patient's pupils and papillary reactions to light.

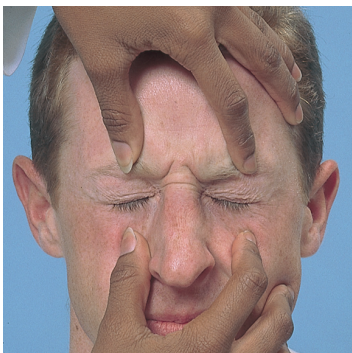
- **CN V (trigeminal).** To assess the sensory component of the trigeminal nerve, ask your patient to close his eyes and then touch him with a wisp of cotton on his forehead, cheek,



and jaw on each side (see photo at left). Next, test pain perception by touching the tip of a safety pin to the same three areas. Ask him to describe and compare both sensations. To test the motor component, ask him to clench his teeth while you palpate the temporal and masseter muscles (see photos at bottom of page 17). Note the strength of the muscle contraction; it should be equal bilaterally. If your patient isn't alert, test his corneal reflex by lightly touching the cornea with a fine wisp of cotton. Look for the normal reaction of blinking of the eyes. (Note: Corneal reflex testing isn't done on an alert patient.)

ton. Look for the normal reaction of blinking of the eyes. (Note: Corneal reflex testing isn't done on an alert patient.)

- **CN VII (facial).** To assess the sensory component, test taste by placing items with various tastes on the anterior portion of your patient's tongue, for example, sweet, sour, and bitter. To test motor function, observe his face for symmetry at rest and while he smiles, frowns, and raises his eyebrows. Then have him close both eyes tightly. Test muscle strength by attempting to open his eyes (see photo at left).

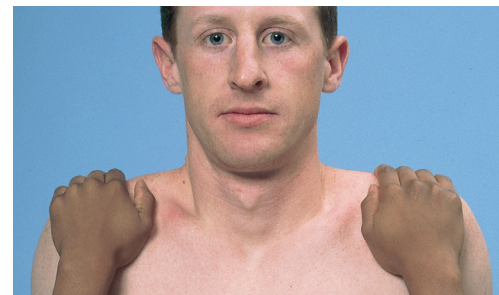


- **CN VIII (acoustic).** To assess this nerve, use Weber's test—strike a tuning fork lightly against your hand and place the vibrating fork on your patient's forehead at the midline or on the top of his head—and the Rinne test—strike the tuning fork against your hand and place the vibrating fork over his mastoid process.

- **CN IX (glossopharyngeal) and CN X (vagus).** Test these nerves together because their innervation overlaps in the pharynx. Listen to your patient's voice. Then check his gag reflex by touching the tip of a

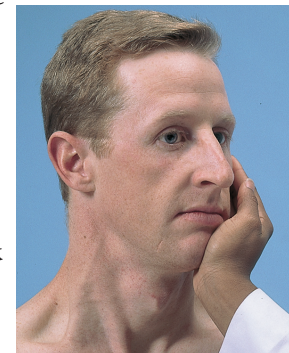
tongue blade against his posterior pharynx and asking him to open wide and say "ah." Watch for symmetrical upward movement of the soft palate and uvula and for the midline position of the uvula.

- **CN XI (spinal accessory).** Assess this nerve by testing the strength of the sternocleidomastoid muscles and the upper



portion of the trapezius muscle (see photo above).


- **CN XII (hypoglossal).** Observe your patient's tongue for symmetry. His tongue should be midline without tremors or muscle twitching. Test tongue strength by asking him to push his tongue against his cheek as you apply resistance (see photo at right).



Assessing motor function

When assessing motor function, you'll want to look at both sides of your patient's body simultaneously. On inspection, note any asymmetry of muscle; unilateral atrophy will often indicate weakness. To assess the upper extremities, have your patient raise his arms parallel to the floor or bed, and then have him resist when you try to push them down. You'll do the same for the lower extremities, having him raise his legs and resist when you push them down. You can also have him grasp your fingers in his fist, and then ask him to let go. If he can't let go on command, it's indicative of neurologic injury.

Visualizing pupil size



To test for pronator drift, have your patient close his eyes so he can't compensate and extend his arms, palms up, in front of him. Look for one arm to sway from its original position: a subtle indicator of weakness.

Assessing pupillary response

Now, we'll move on to pupillary response. Along with eye motion, pupillary response is controlled by cranial nerves III, IV, and VI. Normal pupils are of the same size bilaterally, about 2 to 6 mm and round (see *Visualizing pupil size*). About 15% of people have one pupil up to 1 mm smaller than the other; this is a normal variant known as anisocoria.

To check pupil reactivity, bring a small beam of light in from the outer canthus of one eye; the normal response is for both pupils to react equally and briskly. Keep in mind that medications, surgery, and blindness can affect pupil size, shape, and reactivity. The hallmark sign of severe neurologic injury is a change in pupil size and reactivity. Eye motion is tested by asking your patient to follow your finger as you trace the letter H in front of him. This is known as extraocular movement, or EOM. Document any inability to follow your finger.

The focused assessment

Although a thorough neurologic assessment yields valuable information, at times you'll need to perform a focused neurologic assessment. You may have a patient with a neurologic diagnosis who develops a change. More likely, you may have a patient with another diagnosis who develops a neurologic deficit. In these cases, it isn't necessary to perform the entire assessment as previously described. Limit your examination to LOC, motor strength, and pupillary reactivity. You'll also want to include other assessments you feel may yield im-

portant data. For example, if your patient develops slurred speech, you'll want to include an examination of the cranial nerves involved with speech.

Helpful tips

In performing frequent neurologic assessments, I've found the following information to be helpful.

Keep a cheat sheet. Remembering the function of each cranial nerve or the terminology to describe deficits is overwhelming. Consult your cheat sheet for accurate documentation or when discussing your findings with the healthcare provider, as well as to determine what additions you need if you perform a focused neurologic assessment.

Explain the assessment to your patient and his family before you begin. Many people are frightened when they, or a loved one, develop a neurologic injury, so they can become frustrated when you ask them to do such seemingly silly things as sticking out their tongues. Explain to your patient upfront that you'll be asking him to answer a series of questions and perform commands that may seem frivolous but are important indicators of brain function. I also instruct family members not to answer questions for the patient, even if he seems to be struggling to respond.

Peak performance

Performing a neurologic assessment can be scary. But if you take your time and use the proper resources, you can perform a solid neurologic assessment no matter what. ■

Learn more about it

Bickley LS, Szilagyi PG. *Bates' Guide to Physical Examination and History Taking*. 10th ed. Philadelphia, PA: Lippincott Williams & Wilkins; 2009:671-689.

Health Assessment Made Incredibly Visual! Philadelphia, PA: Lippincott Williams & Wilkins; 2007:177-189.

Smeltzer SC, Bare BG, Hinkle JL, Cheever KH. *Brunner & Suddarth's Textbook of Medical-Surgical Nursing*. 11th ed. Philadelphia, PA: Lippincott Williams & Wilkins; 2008:2143-2152.

Follow these steps to perform a successful neurologic assessment.

